The Effects of Gonadal Steroid Hormones on Tooth Development, Growth, and Maintenance

Hayley Behr

First Reader: Dr. Lisa Whitenack

Second Reader: Dr. Lauren Rudolph



Department of Biology

Allegheny College

Meadville, Pennsylvania

Spring 2021

Abstract

Teeth are vital organs that not only function to cut, grind, and crush food; they can also play a larger role in a person's systemic health. To date, it has been hypothesized that harmful bacteria from tooth infections can reach other areas of the body through bone cavities, blood, or lymph vessels, and along nerves, causing harm to the cardiovascular and neurological systems. From a public health perspective, proper development, growth, and maintenance of a person's teeth throughout their lifetime are important to protect other vital organs. It is important not only to understand teeth but to also understand the regulatory factors that influence them. Gonadal steroid hormones (e.g. estrogen, testosterone & progesterone) serve as regulatory molecules in the teeth. This paper aims to draw upon the literature to comprehensively explain the role that these hormones play in tooth growth, development, maintenance, and ultimately systemic health. Tooth development encompasses both tooth formation and growth. During these processes, gonadal hormones have been shown to play a role in hard tissue formation and the tooth-eruption process. Hard tissue formation relies on osteoblasts and odontoblasts to act as building blocks for dentin, enamel, and cementum. These cells respond to both testosterone and estrogen through transcriptional regulation. Both testosterone and estrogen act as a ligand and bind to a receptor on the target cell. This steroid-receptor complex moves through the cell and binds to the DNA to promote gene transcription which increases cell differentiation. Additionally, higher intrauterine testosterone levels present in the male fetal circulation levels and diffused to females with a twin brother is hypothesized to explain why males and females with a male twin may have larger crown intercuspal dimensions. The surges of testosterone are hypothesized to promote larger crown height and length dimensions through increased transcriptional regulation. Furthermore,

gonadal hormones have been hypothesized to affect a difference in primary tooth eruption times between boys and girls. The common hypothesis behind this is that early secretion of both estrogen and testosterone in girls causes an earlier tooth eruption. Tooth maintenance is the process where teeth are preserved throughout a person's lifetime. In the literature, there are two topics regarding the maintenance of teeth: cavity appearance and periodontal disease. Normal hormonal fluctuations of estrogen in females affect the saliva formation process which is hypothesized to harm processes that preserve teeth from disruptions in the normal oral microflora. Additionally, evidence from rodent experimentation showed that higher concentrations of testosterone and estrogen may correlate to increases in cavity appearance. Also, increased levels of periodontal disease have been noted during times of significant gonadal hormone changes in puberty, pregnancy, menopause, post-menopause, and aging populations. Future research in this field needs to focus on further identifying and describing the links between gonadal hormones, dental health, and systemic health. This will ensure that doctors, dentists, and other practitioners are properly educated to ensure beneficial treatments for patients.

Introduction

Teeth are vital organs with a diverse set of functions that contribute to a person's daily function (Clark et al., 2019). They are more than just a hard surface that functions to cut, grind, and crush food; they can also play a larger role in a person's systemic health (Bergqvist, 2003). This idea has existed for centuries, dating back to the ancient Egyptian physicians who knew tooth infections needed to be treated carefully to prevent life-threatening complications (Olsen & Van Winkelhoff, 2000). In 1891, the first written hypothesis was published suggesting that oral microorganisms can affect other parts of the body (Olsen & Van Winkelhoff, 2000). After this,

many different scientists followed suit, hypothesizing that decaying teeth could potentially lead to arthritis, heart disease, tonsillitis, or endocarditis (Billings, 1914). The common claim was that bacteria and other harmful microorganisms from tooth infections reach other areas of the body through bone cavities, blood or lymph vessels, and along nerves (Olsen & Van Winkelhoff, 2000). However, it wasn't until the last few decades that an increasing number of scientists have begun looking into each of these hypotheses and providing scientific evidence to support that tooth infections may cause larger complications.

Over the last twenty-five years, a large number of epidemiological investigations have discovered a link between chronic, poor oral health and cardiovascular disease (Sanz et al., 2010). The chronic over-occurrence of harmful bacteria on the teeth and gums has been associated with disorders in the cardiovascular system. This source of harmful bacteria can cause cavities, infections, and periodontal disease (Sanz et al., 2010). Teeth offer a non-shedding surface that allows for consistent bacteria development and colonization (Sanz et al., 2010). Recently, researchers have found evidence correlating harmful bacteria to future stroke, increased heart attack risk, and other long-term cardiovascular conditions (Pussinen et al., 2007; Renvert et al., 2006).

Additionally, tooth infections have been linked with brain infections. Levine (2013) explains that a tooth infection, if not properly treated, has the potential to spread throughout the body, including to the brain. His evidence dates back to a case study in 1985 when a thirty-year-old patient died from complications of a tooth infection that spread from large amounts of infected tissue leaking into the sinus and causing a sinus infection that spread into the brain (Levine, 2013). Furthermore, a brain abscess can occur in a person experiencing a dental infection (Azenha et al., 2012; Corson et al., 2001). A brain abscess is a rare infection with a

high rate of mortality that develops in the brain parenchyma (Corson et al., 2001). Therefore, dental infections have been reported to be a source of bacteria that may give rise to a brain abscess (Azenha et al., 2012).

From a public health perspective, proper development, growth, and maintenance of a person's teeth throughout their lifetime are important to protect other vital organs in a person's body (Sanz et al., 2010). It is important not only to understand teeth, but to also understand the many regulatory factors that influence the development, growth, and maintenance of them (Clark & Levin, 2019). These regulatory substances include genes, hormones, regulatory factors, and morphogens (Jernvall & Thesleff, 2012). Proper tooth growth and shape are based largely on interactions between correctly functioning regulatory factors (Li et al., 1998). Hormones are specific regulatory molecules that have strong effects on the major determinants of the development and the integrity of the skeleton and the oral cavity (Anstead et al., 1997; Freeman et al., 2001; Santen et al., 2019). Thus, normal, lifetime fluctuations of hormones are important in the proper development and maintenance of teeth (Li et al., 1998).

Gonadal hormones, also called sex hormones, are a category of steroid hormones that have major effects on the development and growth of the skeleton and oral cavity (Freeman et al., 2001). Androgens (e.g. testosterone) are found in both males and females. One specific type of Androgen, testosterone, plays a role in tooth remodeling, which is a process where mature hard tissue is removed and new tissue is formed (Freeman et al., 2001). This process is controlled by osteoblasts, odontoblasts, and osteoclasts. This gonadal steroid hormone also plays an important role in the maintenance of tooth mass, osteoblast and odontoblasts proliferation, and

differentiation, and inhibits osteoclastic function in both males and females (Freeman et al., 2001).

Also, estrogen is another type of gonadal steroid hormone that has been hypothesized to function in tooth development, growth, and maintenance. In both males and females, estrogen is also associated with tooth remodeling by osteoblasts, odontoblasts, and osteoclasts (Anstead et al., 1997; Santen et al., 2019).

Just as normal functioning teeth are important, the relationship between gonadal steroid hormones and teeth is important for the quality of a person's overall health. Normal fluctuations of gonadal steroids hormones are important to ensure that teeth undergo proper development, growth, and maintenance (Anstead et al., 1997; Freeman et al., 2001; Santen et al., 2019). If there are any disruptions to the processes that regulate teeth, then there may be large consequences to a person's general health because teeth can impact a person's cardiovascular and neurological systems (Olsen & Van Winkelhoff, 2000; Sanz et al., 2010). Due to the importance of this topic, there is an increased need for a comprehensive review that is absent in the present literature. The goal of this paper is to draw upon the literature and explain how gonadal steroid hormones affect tooth development, growth, maintenance, and systemic health.

Mechanisms of Tooth Development & Growth

In mammals with teeth, tooth development begins with tooth formation (Figure 1). Generally, tooth formation is regulated by inductive interactions between epithelial and mesenchymal cells that are derived from the ectoderm (Thesleff & Nieminen, 1996). Before the first stage of development, a dental lamina appears in the dental epithelium tissue. This causes

thickening in the epithelium which restricts the future tooth from forming laterally instead of vertically (Jernvall & Thesleff, 2012). From within the dental lamina, the first stage of development commonly known as the initiation stage occurs (Thesleff & Nieminen, 1996). In this stage, individual teeth are initiated by gradual restrictions of the sonic hedgehog gene (Shh) and the pituitary homeobox (Pitx2) in specific domains (placodes) that give rise to teeth (Jernvall & Thesleff, 2012).

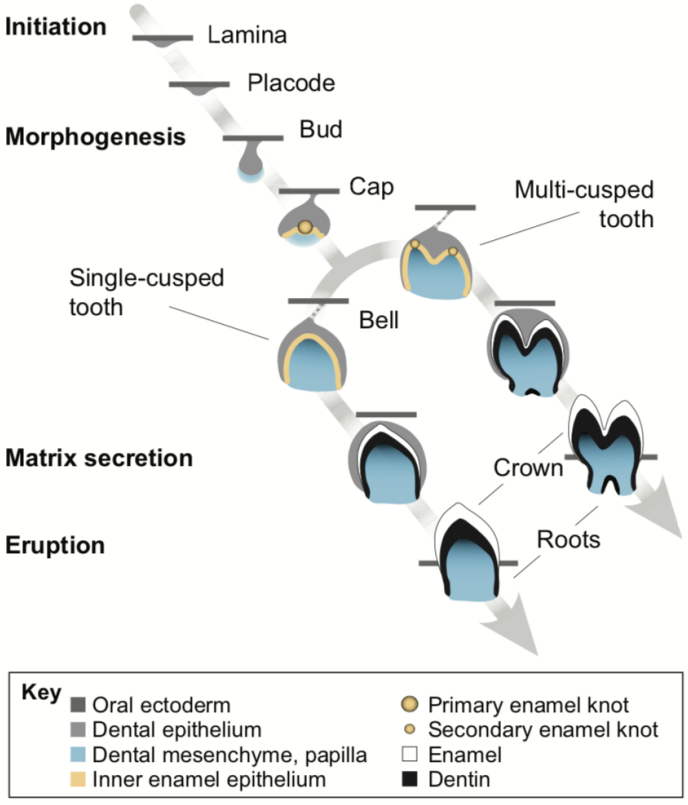

Figure 1. The principal stages of tooth development. The key explains the important parts of the tooth developed in each stage. (Figure is from Jernvall & Thesleff (2012)).

Following the initiation stage, the morphology of individual teeth begins to appear during a series of stages called the bud, cap, and bell. These stages are important because the correct function of teeth depends on the patterns established in them (Jernvall & Thesleff, 2012). The

bud stage starts during the eighth week of human intrauterine development and serves as the first emergence of the tooth's enamel by swellings formed in the dental lamina under the influence of the mesenchymal cells (Rathee & Jain, 2020). In mammals with multi-cusped teeth, there is an extra step of development that happens during this stage. This is when a primary enamel knot forms and expresses molecular signals to help drive the development of teeth. An enamel knot will appear in every location where a future cusp will form on the tooth (Jernvall & Thesleff, 2012). Additionally, secondary enamel knots will occur to indicate cusp height and mineralization order, and this guides tooth shape development (Jernvall & Thesleff, 2012). Next, the cap stage occurs; this is where species-specific cusp patterns form, and the tooth grows to its final size (Thesleff & Nieminen, 1996). Here, the inner epithelium cells create a layer that defines the shape of the tooth's crown and maintains the enamel's shape (Rathee & Jain, 2020). Furthermore, the mesenchymal cells from the dental papilla and the dental follicle begin to surround the tooth (Rathee & Jain, 2020). Simultaneously, the enamel epithelium cells proliferate to form the Hertwig's epithelial root sheath where dental papilla forms, giving rise to the tooth pulp and dentin of the eventual tooth (Fujiwara & Fujimura, 2019). In the last stage, the bell stage, the dental lamina disintegrates and begins to become ready for the formation of hard tissue (Thesleff & Niemien, 1996).

Hard tissue formation possesses similar functional, developmental, and anatomical similarities to bone development (Dale et al., 2002). The growth and maintenance of hard tissue in the tooth depend on odontoblasts and osteoblasts (Dale et al., 2002). Hard tissue formation dictates the formation of species-specific cusp patterns. As the tooth begins to grow to its final size, and cells continue to differentiate, four important formations take place: dentin, enamel,

root, and cementum (Rathee & Jain, 2020; Thesleff & Nieminen, 1996). Enamel was laid out previously during the bud stage, however, the dentin, root, and cementum do not begin development until after the bell stage (Thesleff & Nieminen, 1996). Dentin formation begins when cells from the epithelium induce the dental papilla to form odontoblasts during the bud stage. These cells secrete an unmineralized dentin matrix which is known as the pre-dentin. At 5 μm thick, the pre-dentin begins to mineralize, forming spherical zones called calcospherites that fuse to form mineralized dentin (Rathee & Jain, 2020). Enamel formation began during the bud stage, however, the process continues when the dentin mineralizes. The enamel epithelium cells differentiate into an enamel matrix. Once this enamel matrix is laid down, mineralization begins by the secretion of calcium and phosphate ions into the matrix. As more matrices are secreted and mineralized, the enamel matures in size (Rathee & Jain, 2020). Furthermore, root formation occurs when the Hertwig's root sheath begins to grow and enclose the dental papilla. This process outlines the shape of the root (Rathee & Jain, 2020). Finally, the last hard tissue formation is the cementum. Following the completion of the root, the Hertwig's root sheath fragments and allows the cells from the dental follicle to meet with the root dentin. These cells begin to differentiate and form cementoblasts that create a mineralized cementum matrix.

After hard tissue formation occurs, periodontium formation takes place (Noden, 1984). Cells of the dental follicle differentiate into fibroblasts that orient themselves into bundles in the root and form the periodontal ligaments, gingiva, and alveolar bone (Noden,1984). Additionally, nerve and blood vessel formation take place here.

Once the nerve and vascular formation occur, the tooth eruption begins; the tooth enters the mouth and becomes visible (Noden, 1984). This can be broken down into five stages:

pre-eruptive movements, intraosseous eruption, mucosal penetration, pre-occlusal eruption, and post-occlusal eruption (Figure 2) (Marks et al., 1995; Marks & Schroeder, 1996). During the beginning stages of tooth development in the jaw, there are small pre-eruptive movements that continue until root formation (Marks et al., 1995; Marks & Schroeder, 1996). Next, the intraosseous eruption occurs through bone resorption and the roots of the primary teeth. This stage ends before oral mucosal penetration where eruption slows down (Marks et al., 1995; Marks & Schroeder, 1996). Once the eruption slows, it moves through the gingiva (gums). Here, the gums provide support for the tooth and closure for the root apex (Marks et al., 1995; Marks & Schroeder, 1996). Following this, eruption and alveolar growth continue at a slow rate until full eruption is complete (Marks et al., 1995; Marks & Schroeder, 1996).

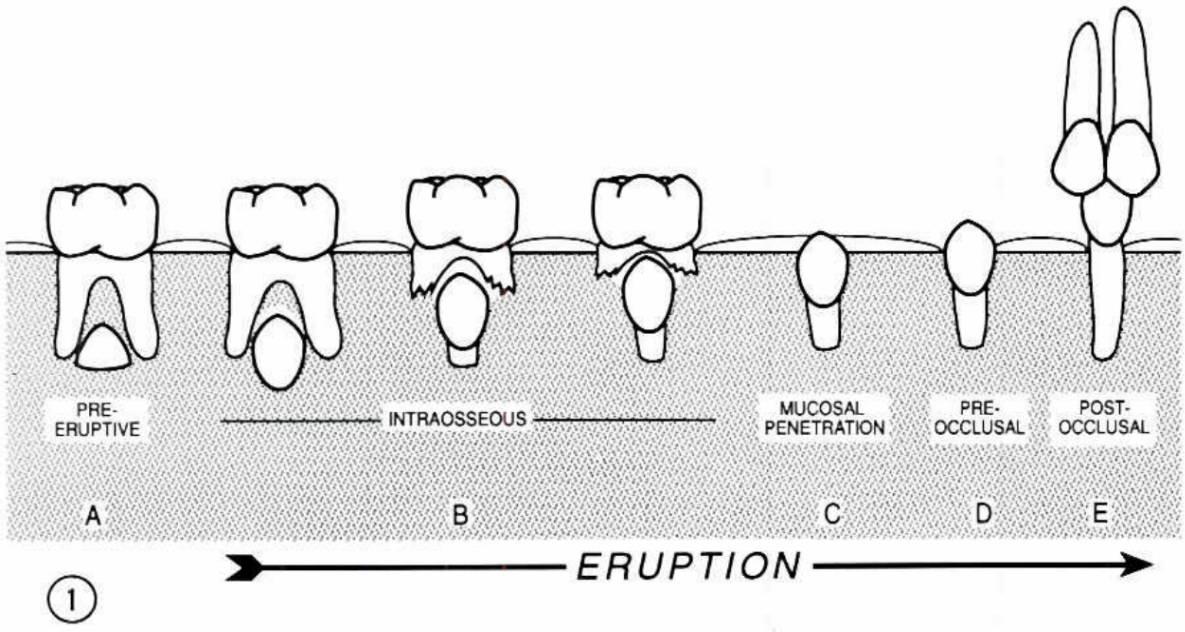

Figure 2. The process of tooth eruption is broken down into five stages: pre-eruptive movements (A), intraosseous eruption (B), mucosal penetration (C), pre-occlusal eruption (D), and post-occlusal eruption (E). The gray layer represents the oral epithelium and the white layer represents the gingiva (gums). (Figure is from Marks et al. (1995)).

The process of how teeth move during an eruption is still unknown, but some common

hypotheses have been suggested about how this process occurs: 1) the tooth is pushed upward into the mouth by the growth of the tooth's root, 2) the tooth is pushed upward by the growth of the bone around the tooth and, 3) the tooth is pushed upward by vascular development (Noden, 1984).

In human development, dentition is considered diphyodont, meaning humans have two generations of functional teeth during their lifetime that will develop and erupt (Hovorakova et al., 2018). These are twenty deciduous teeth and thirty-two permanent teeth. The permanent teeth start to develop in the jaws at birth and continue after birth (Hovorakova et al., 2018). Permanent teeth develop under the same process as primary tooth development (Hovorakova et al., 2018). However, during the final stages of root formation in the primary teeth, the dental lamina degrades and the root connection between the primary and permanent teeth is lost (Holt, Roberts, & Scully, 2001; Yu & Klein, 2020). The permanent teeth continue to grow in size with the development of the skull and eventually push out the primary teeth (Table 1) (Holt, Roberts, & Scully, 2001; Yu & Klein, 2020).

Table 1. Average ages of tooth eruption in humans in both primary and permanent teeth. (Table is from Holt, Roberts, & Scully, (2001)).

	Upper teeth	***Lower teeth***
Primary teeth	(months)	
Central incisors	8-13	6-10
Lateral incisors	8-13	10-16
Canines (cuspids)	16-23	16-23
First molars	13-19	13-19
Second molars	25-33	23-31
Permanent teeth	(years)	
Central incisors	7-8	6-7
Lateral incisors	8-9	7-8
Canines (cuspids)	11-12	9-10
First premolars (bicuspids)	10-11	10-12
Second premolars (bicuspids)	10-12	11-12
First molars	6-7	6-7
Second molars	12-13	11-13
Third molars	17-21	17-21

By the end of the proper development and growth, a healthy tooth should contain a crown made of enamel that surrounds dentin and a root with no enamel covering (Figure 3) (Holt, Roberts, & Scully, 2001). The tooth will also contain some supporting structures: a vital pulp (nerve), periodontal ligament, and alveolar bone (Holt, Roberts, & Scully, 2001). Additionally, the periodontal ligament attaches to the cementum of the root and dentin. This is covered by the gingiva and a gingival crevice where the gingiva folds down to meet the dentin (Holt, Roberts, & Scully, 2001).

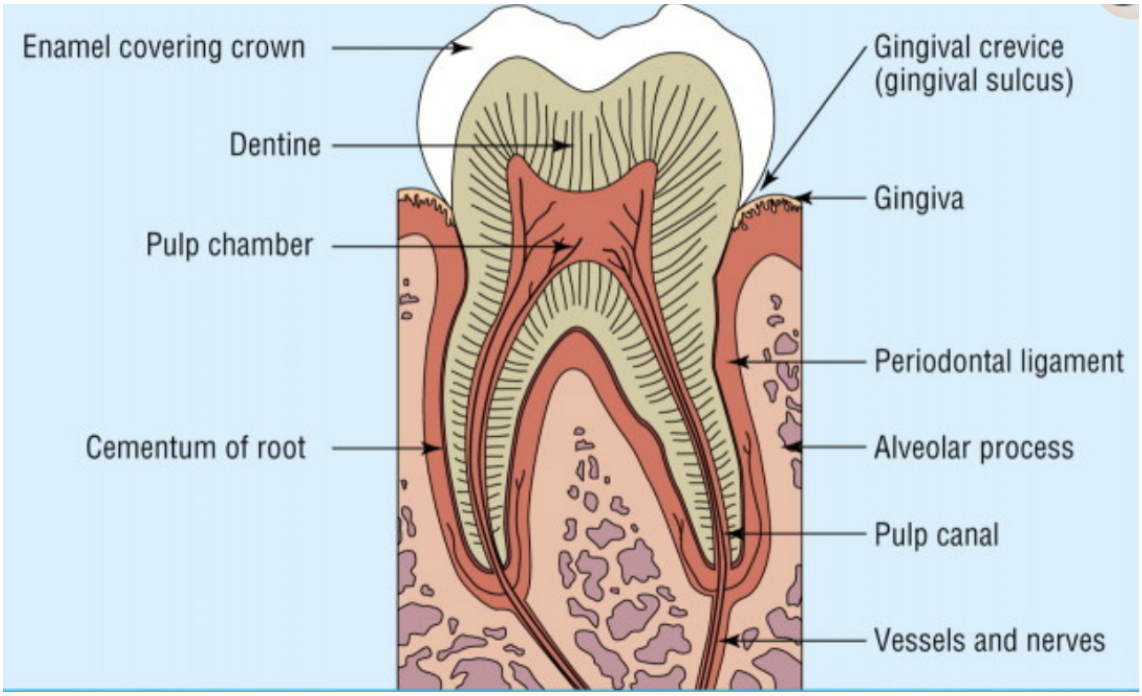

Figure 3. Diagram of a healthy tooth and supporting structures. (Figure is from Holt, Roberts, & Scully (2001)).

Gonadal Steroid Hormones

The development, growth, and maintenance of teeth are controlled by many regulatory factors. This includes genes, hormones, transcription factors, and morphogens (Jernvall & Thesleff, 2012). Proper development and growth are based largely on correct interactions between these mechanisms (Li et al., 1998). This applies to a series of cellular and molecular mechanisms that work together to promote tooth development and eruption into the oral cavity (Boabaid et al., 2004). Hormones are one specific regulatory factor that plays an important role in modulating continual growth and development of the oral cavity (Anstead et al., 1997; Freeman et al., 2001; Santen et al., 2019). For example, different hormones can work together to promote osteoclastogenesis by inhibiting the expression of a series of regulatory factors that enhance osteoblast production (Boabaid et al., 2004).

Steroid hormones function by first passing through the cell membrane of a target cell (Figure 4) (Miller, 1988). Outside the cell, steroid hormones act as ligands and bind to receptors embedded in the cell membrane or diffuse through the cell to bind to receptors in the cytoplasm (Miller, 1988). After this process occurs, the steroid-hormone receptor complex moves to the nucleus and binds to DNA sequences called hormone response elements (HREs) to stimulate or inhibit the production of specific messenger RNA (mRNA) through transcription (Miller, 1988). If stimulated, the mRNA can continue along with the cellular process into translation and protein synthesis which leads to cellular differentiation (Miller, 1988). This is not the only known model for how steroid hormones function, steroid hormones also may work in a membrane-initiated, neurotransmitter-like function (Rudolph et al., 2016). However, steroid functions on teeth primarily happen through transcriptional regulation (Miller, 1988).

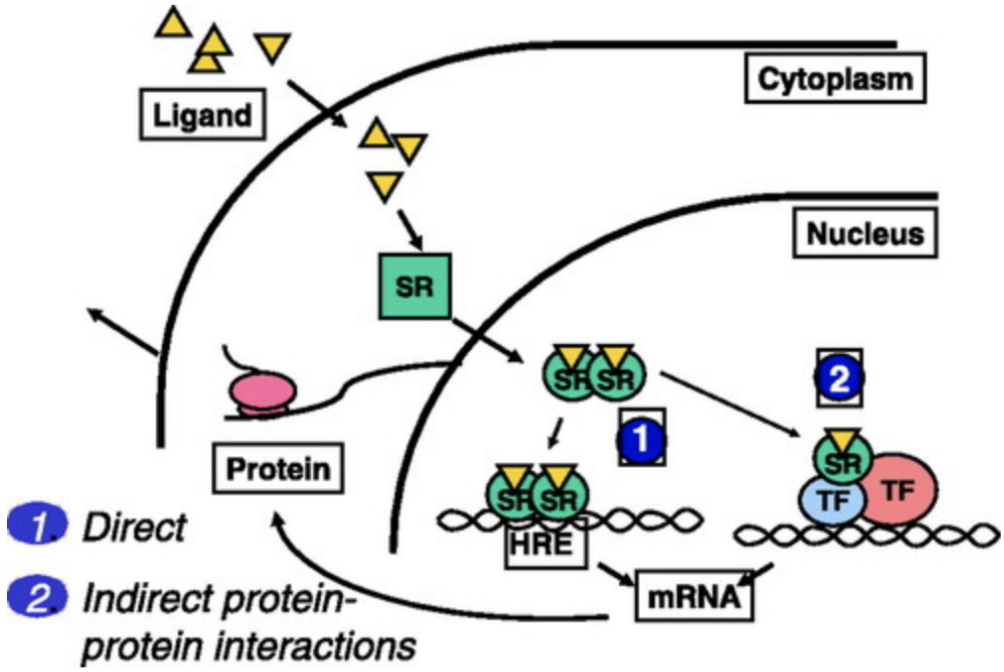

Figure 4. Transcriptional action by steroid receptors (SR). These factors are activated by ligands (i.e. estrogen or testosterone) and promote transcription after binding to hormone response elements (HRE) on DNA. This is one mechanism by which gonadal steroid hormones can affect osteoblasts and osteoclasts during the process of tooth development and growth. This figure is cited from Wierman (2007).

Gonadal hormones are hypothesized to have major effects on the development and growth of the skeleton and the oral cavity (Anstead et al., 1997; Freeman et al., 2001; Santen et al., 2019). These important steroid hormones are categorized into two main groups that have been hypothesized to affect teeth, testosterone and estrogen (e.g. 17-β-estradiol) (Anstead et al., 1997; Freeman et al., 2001; Santen et al., 2019). Although there are other gonadal steroids (e.g. progesterone), they have not been shown to have any significant biological actions that affect teeth (Güncü, Tözüm, & Çağlayan, 2005).

One type of Androgen, testosterone, is found in both males and females. In males, its main reproductive functions are in spermatogenesis and the development of secondary sexual characteristics (Freeman et al., 2001). However, in females, their main function is in the

hormonal cascade that starts puberty and aids in growth, maintenance, and repair of major organs (Freeman et al., 2001). In both males and females, testosterone plays an important role in the maintenance of tooth mass, osteoblast and odontoblast proliferation, and differentiation, and inhibiting osteoclast function (Freeman et al., 2001). The reason that testosterone has such functions is that the building blocks of teeth (e.g. osteoblasts & odontoblasts) contain testosterone receptors (Dale et al., 2002). These receptors have been hypothesized to increase the number of osteoblasts and odontoblasts, which aids in hard tissue formation to increase tooth mass (Freeman et al., 2001). Additionally, there is also evidence that suggests testosterone may play an inhibitory role in the pathway that regulates the breakdown of teeth by osteoclasts because there are also steroid receptors found in osteoclasts (Dale et al., 2002). Under high concentrations of testosterone, it may have an inhibitory effect on osteoclast formation through transcriptional inhibition in the same process of transcriptional regulation (Freeman et al., 2001). This function helps maintain tooth mass because this pathway is associated with decreased tooth mass density which is often associated with enamel breakdown and broken teeth (Freeman et al., 2001).

Estrogen is another type of gonadal hormone that has been hypothesized to function in tooth development, growth, and maintenance. Estrogens play a crucial role in the reproductive system and the maintenance of secondary sexual characteristics in females (Anstead et al., 1997; Santen et al., 2019). In males, estrogens play a critical role in male sexual function and are essential for modulating libido, erectile function, and spermatogenesis (Dale et al., 2002). In both males and females, estrogen is hypothesized to be a transcriptional regulator, acting similarly to how testosterone does to promote cell differentiation (Anstead et al., 1997; Santen et al., 2019).

Additionally, enzymes convert testosterone to estrogen (Mascarenhas et al., 2002). This is particularly important when considering the effects these hormones have on teeth because what seems like the effect of one gonadal steroid hormone could actually be influenced by another (Mascarenhas et al., 2002). This is especially important during times where estrogen concentrations may be significantly low in a person (Mascarenhas et al., 2002).

In both males and females, the concentrations of these hormones vary throughout a person's lifetime (Dimitrakakis & Bondy, 2009). In males, the first increase in testosterone is during intrauterine development due to the presence of the Y-chromosome (Figure 5) (Decaroli & Rochira et al., 2009; Riberio et al., 2013). Then, the next influx of testosterone comes during puberty and continues to increase and level off until a person is in their early forties. Finally, as a person ages, testosterone levels decline until the individual reaches the end of his life (Decaroli & Rochira et al., 2009). Testosterone levels in females are also stable at low concentrations until puberty. During puberty, testosterone levels in females increase at a low rate and remain stable until they reach menopause. Then the concentration of testosterone decreases to the concentration it was at before puberty (Figure 5) (Decaroli & Rochira et al., 2009). However, the concentration of testosterone is higher than estrogen levels are after menopause (Decaroli & Rochira et al., 2009; Riberio et al., 2013).

Like testosterone, estrogen concentrations fluctuate throughout a person's lifetime. Estrogen levels in males increase around the age of puberty, however, the increase is not as significant as the increase in testosterone levels (Figure 5) (Decaroli & Rochira et al., 2009). Additionally, estrogen levels in males follow the same pattern as testosterone throughout a person's life, however, the concentration is also much lower (Decaroli & Rochira et al., 2009).,

Estrogen concentrations are relatively stable from birth until puberty in females where they undergo a significant influx (Figure 5) (Decaroli & Rochira et al., 2009). After puberty ends, estrogen levels stay at high concentrations until a female reaches menopause when the levels drop back to the concentration they were at before puberty (Decaroli & Rochira et al., 2009). The estrogen levels remain low and stable until a female reaches the end of their life (Dimitrakakis & Bondy, 2009). Overall, it is clear that normal fluctuations of both testosterone and estrogen levels are important in the proper development, growth, and maintenance of teeth in males and females (Li et al., 1998).

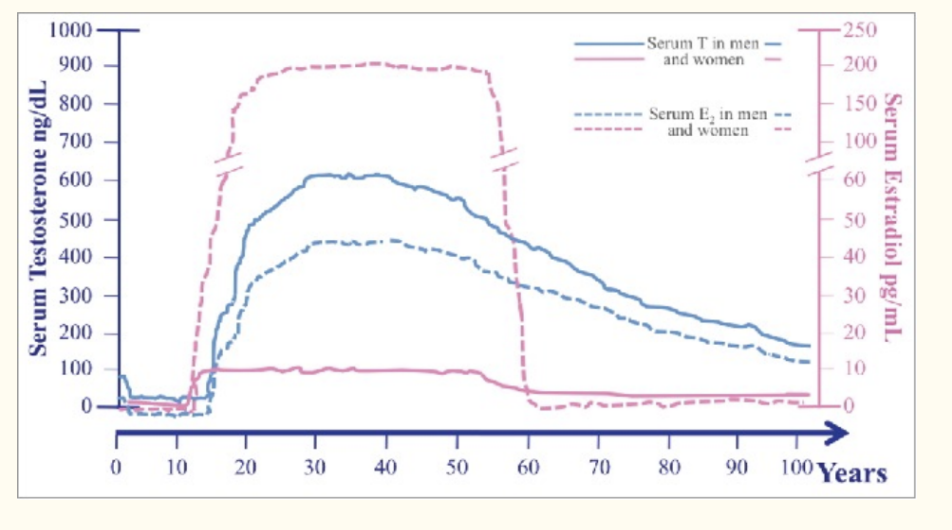

Figure 5. Average concentrations of estrogen/estradiol (E2) (dashed lines) and testosterone (T) (solid lines) in males (blue lines) and females (pink lines) across a person's lifespan. The x-axis represents years, which the y-axis represents serum hormone levels (pg/mL). This figure is cited from Decaroli & Rochira (2017).

Gonadal Hormones & Their Effect on Tooth Development & Growth

During the development of teeth, gonadal steroid hormones act in a series of cellular and molecular mechanisms that work together to promote tooth development and eruption into the oral cavity (Boabaid et al., 2004). The main effect they have on these processes is

during hard tissue formation. During this process, hard tissue formation relies on osteoblasts and odontoblasts to act as building blocks for dentin, enamel, and cementum (Dale et al., 2002).

Osteoblasts and odontoblasts respond to testosterone through transcriptional regulation (Wierman, 2007; Wiren et al., 1997).Testosterone acts as a ligand and promotes gene transcription and protein synthesis which increases the number of osteoblasts and odontoblasts present, acting subsequently to build up dentin, enamel, and cementum (Figure 4) (Dale et al., 2002; Wierman, 2007; Wiren et al., 1997). Estrogen also acts as a regulatory factor in this way. The estrogen receptors (ERɒ & ETβ) are also expressed in developing osteoblasts and odontoblasts (Eriksen et al., 1988; Heldring et al., 2007; Hietala, Larmas, & Salo, 1998). In this case, estrogen acts as a ligand and binds to a specific receptor on the target cell or inside the cytoplasm of the target cell (Eriksen et al., 1988; Heldring et al., 2007; Hietala, Larmas, & Salo, 1998). The estrogen-receptor complex promotes differentiation through transcription and protein synthesis (Figure 4) (Hietala, Larmas, & Salo, 1998). Like testosterone's effects, this cellular differentiation of osteoblasts and odontoblasts helps to build dentin, enamel, and cementum during hard tissue formation (Dale et al., 2002).

Another gonadal steroid influence on teeth is during male intrauterine development when a surge of testosterone occurs around seven to nine weeks of development and increases until levels peak around week fourteen (Riberio et al., 2013). These higher testosterone levels present in the fetal circulation levels are a factor in the sexual dimorphism that exists between the teeth of males and females (Riberio et al., 2013). The results of Riberio et al. (2013) suggest that this influx of testosterone and the presence of the Y-chromosome is a reason that males develop larger teeth than females.

Furthermore, this relationship between intrauterine hormone surges and increased crown dimensions has also been noted in females with a twin brother (Dempsey, Townsend, & Richards, 1999; Ribeiro, 2012). The influx of testosterone that males experience in utero can diffuse to the female twin (Dempsey, Townsend, & Richards, 1999; Ribeiro, 2012). This surge affects the sister because it exposes the fetus to higher concentrations of testosterone which may influence their development (Ribeiro, 2012). This surge in females with a twin brother has been linked to increased tooth crown sizes that are not present in females without twin or female twin pairs (Dempsey, Townsend, & Richards, 1999; Ribeiro, 2012).

Gonadal steroid hormonal surges are important in the development of crown intercuspal dimensions during the cap stage (Ribeiro et al., 2013). Here, the tooth grows to its final size and the epithelium cells create a layer that defines the shape of the tooth crown (Rathee & Jain, 2020). These testosterone surges are hypothesized to promote larger crown height and length dimensions through the same process of transcriptional regulation and protein synthesis which increases osteoblast and odontoblast differentiation (Riberio et al., 2013).). Following the expression of mRNA after transcription is initiated by gonadal steroid hormones, translation occurs and proteins are expressed in the osteoblast and odontoblasts (Riberio et al., 2013). Seven proteins have been identified to increasing tooth dimensions: four proteins specific to the enamel (amelogenin isoforms X and Y, enamelin and ameloblastin), and three non-specific proteins (serum, albumin and, antithrombin) (Stewart et al., 2016). Ultimately, this is how hard tissue structures increase in size during tooth development (Stewart et al., 2016).

Additionally, gonadal hormones have been hypothesized to affect a difference in primary tooth eruption times between males and females. A study by Garn et al. (1967) examined the different eruption stages in males and females. They found that, on average, females tend to have

tooth eruption around two months earlier than males (Table 2) (Garn et al., 1967). The common hypothesis behind this is that early secretion of both estrogen and testosterone in females causes an earlier eruption of teeth (Garn et al., 1967). Also, other studies have reported that high concentrations of testosterone administered to male rhesus monkeys dramatically increased tooth eruption (Van Wagenen et al., 1950). Since the process of how teeth move during an eruption is still unknown, there is no evidence for why gonadal steroid hormones have this effect (Garn et al., 1967; Noden, 1984; & Van Wagenen et al., 1950).

Table 2. The mean age of tooth eruption differs between males and females across each tooth. Generally, mean age eruptions in females tend to be higher than males by an average age of two months. This table is cited from Garn et al. (1958).

SEX DIFFERENCES IN TOOTH CALCIFICATION AND ERUPTION

TOOTH AND STAGE		BOYS		GIRLS		SEX DIFFERENCE (YEARS*)
		NO.	MEAN AGE	NO.	MEAN AGE	
P_1	I	98	2.2	66	1.8	0.34
P_1	II	97	7.4	75	7.2	0.23
P_1	III	46	10.1	47	9.7	0.39
P_1	IV	34	10.9	34	10.3	0.59
P_1	V	24	13.0	16	12.5	0.48
P_2	I	100	3.3	79	3.3	0.00
P_2	II	90	8.2	76	8.0	0.19
P_2	III	33	11.1	31	10.3	0.76
P_2	IV	27	12.2	23	11.3	0.92
P_2	V	18	14.1	14	13.4	0.75
M_1	II	105	4.3	70	4.0	0.25
M_1	III	54	5.8	39	5.7	0.11
M_1	IV	46	6.9	24	6.9	0.02
M_1	V	48	10.3	39	10.6	-0.21
M_2	I	113	3.5	83	3.2	0.31
M_2	II	89	8.9	88	8.7	0.21
M_2	III	40	11.2	39	10.7	0.59
M_2	IV	26	12.7	17	11.8	0.88
M_2	V	22	15.0	15	14.6	0.42
M_3	I	69	9.0	66	9.0	-0.01
M_3	II	34	14.6	19	15.2	-0.55

Gonadal Hormones & Their Effect on Tooth Maintenance

Tooth maintenance is the process where teeth are preserved and maintained throughout a person's lifetime (Güncü, Tözüm, & Çağlayan, 2005). Similar to tooth development and growth, tooth maintenance is also influenced by gonadal steroid hormones (Jernvall & Thesleff, 2012). In the current literature, there are two important topics presented regarding the maintenance of teeth; the first is cavity prevalence and the second is periodontal disease.

Cavity Prevalence

Cavities, otherwise known as advanced dental caries or tooth decay, are one of the most prevalent chronic diseases worldwide (Selwitz, Ismail, & Pitts, 2007). They are often defined as the localized destruction of dental hard tissue from the acidic byproducts caused by bacterial fermentation of carbohydrates (Selwitz, Ismail, & Pitts, 2007). Although dental cavities typically occur on the surface of the tooth, this disease can be seen in both the crown (e.g. cementum, dentin, and enamel) and the root of both primary and permanent teeth (Selwitz, Ismail, & Pitts, 2007). Endogenous Bacteria from our natural microflora (e.g. *Streptococcus mutans*, *Streptococcus sobrinus*, and *Lactobacillus*) may lead to cavities as a result of poor oral health (Selwitz, Ismail, & Pitts, 2007). As a byproduct of the metabolism of fermentable carbohydrates, these bacteria, produce weak organic acids, which causes pH values to drop and calcium, phosphate, and carbonate to diffuse out of the enamel, a process called demineralization (Figure 6)(Selwitz, Ismail, & Pitts, 2007). Tooth demineralization can be reversed when the typical pH is restored by saliva or fluoride. However, if a high rate of demineralization occurs, remineralization oftentimes cannot keep up and cavity formation occurs (Figure 6) (Selwitz, Ismail, & Pitts, 2007).

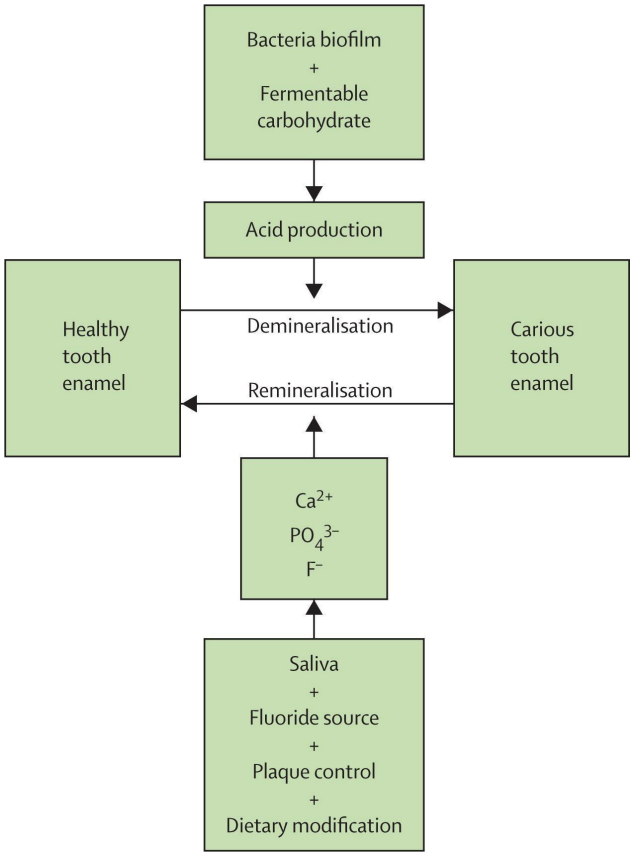

Figure 6. Diagram of the tooth demineralization (destruction) and mineralization (repair) fluctuation that occurs during the cavity formation process. This figure is from Selwitz, Ismail, & Pitts (2007).

Cavity rates in females are typically reported in higher prevalence than males (Lukacs, 2011). In studies that mainly focused on estrogen, some researchers present the hypothesis that due to increased concentrations of estrogen in females compared to males, there are sex differences in cavity formation (Lukacs, 2011; Lukacs & Largaespada, 2006). High cavity rates among females are often explained by two factors: an earlier eruption of teeth in girls due to earlier estrogen fluctuations, thus longer exposure of the tooth to harmful bacteria, and increased estrogen levels which have been associated with lower levels of saliva to combat harmful bacteria (Table 2) (Lukacs, 2011; Lukacs & Largaespada, 2006).

Longer exposure is characterized by the earlier eruption of teeth. In females, this means that there is more time for tooth demineralization (Lukacs, 2011; Selwitz, Ismail, & Pitts, 2007). Although remineralization still occurs, the more times demineralization occurs, the less likely it is that saliva and fluoride will remineralize teeth, and thus, cavities form more often in females (Selwitz, Ismail, & Pitts, 2007).

Females typically have increased fluctuations in estrogen levels during their individual life histories compared to males due to the monthly menstrual cycle. Additionally, fluctuations occur during puberty, pregnancy, menopause, and post-menopause (Lukacs & Largaespada, 2006). Males typically only go through times of large fluctuations during puberty and experience age-dependent decreases of both estrogen and testosterone (Lukacs & Largaespada, 2006). In females, this increase in estrogen during these periods affects saliva production (Lukacs & Largaespada, 2006). Saliva is a fluid that coats the inner surface of the oral cavity and the outer surface of tooth enamel (Lukacs, 2011; Lukacs & Largaespada, 2006). The major functions of saliva for teeth are to deny harmful bacteria an optimal pH, neutralize acids, and prevent tooth demineralization (Lukacs, 2011; Lukacs & Largaespada, 2006). During the demineralization process of teeth, salivary peptides (human beta-defensin-3 (hBD-3), the cathelicidin LL37, and the alpha-defensins HNP1-3 (a mixture of HNP1, 2, & 3) help raise the pH of the tooth surface following the exposure of fermentable carbohydrates (Lukacs, 2011; Lukacs & Largaespada, 2006; Tao et al., 2005). When the salivary rate and thickness are diminished during these times of higher concentrations of estrogen, higher rates of tooth demineralization are reported in females (Lukacs, 2011).

Estrogen has been hypothesized to play a role in the mechanisms of saliva flow because estrogen receptor mRNA and proteins have been found in the salivary glands and oral mucosa which may affect the quality and quantity of saliva flow (Lukacs & Luargaespada, 2006). The initiation of transcriptional regulation in response to increased concentrations of estrogen has been hypothesized to cause transcriptional repression in the salivary glands and oral mucosa's production of saliva (Lukacs & Luargaespada, 2006). This repression of transcription hinders any translation and protein synthesis expression in the salivary glands controlling the production of saliva which may hinder salivary rate and thickness (Lukacs & Luargaespada, 2006). This phenomena has been noted during puberty, menstruation, pregnancy, menopause, and post-menopause (Lukacs & Luargaespada, 2006). Overall, these gonadal hormone fluctuations may contribute to changes in salivary processes.

While hormones fluctuate naturally in humans, we can more directly study the effects on teeth in rodents. Rodents have been used as a viable model for this area of research due to their accelerated oral development and their similarities to the human oral system (Bixler et al., 1956). In the literature, a main topic of research is on the effects of orchidectomy and gonadal steroid hormone manipulation in male rodent models (Bixler et al., 1956; Muhler et al., 1952; Shaw, 1950). In these experiments, testosterone was manipulated in an orchidectomized (castrated) group (low concentrations of testosterone), a control group, and a gonadally-intact testosterone administration group (high concentrations of testosterone-10 mg/kg) (Bixler et al., 1956; Muhler et al., 1952; Shaw, 1950). Evidence from these research studies indicates that cavity appearance in orchidectomized rats was less than control groups (Bixler et al., 1956; Muhler et al., 1952; Shaw, 1950). Additionally, administration of testosterone to control males appeared to increase cavity appearance in teeth (Bixler et al., 1956; Muhler et al., 1952; Shaw, 1950). Overall, these

experiments found evidence that suggested that increased concentrations from the normal amount of testosterone were correlated to increases in rates of cavity appearance. However, researchers noted that testosterone is converted to estrogen, so they could not cause causally related testosterone to increases in cavity appearance because estrogen may have an effect here as well (Bixler et al., 1956; Muhler et al., 1952; Shaw, 1950).

Furthermore, one study researched the effects of ovariectomy (ovary removal) and estrogen manipulation in female rodents (Bixler et al., 1956). They found that estrogen had a significantly more pronounced effect on the severity of cavities produced than testosterone (Bixler et al., 1956). Their results also suggested ovariectomized female rats had fewer numbers of cavities present than the control group (Bixler et al., 1956). Additionally, the female rats treated with 50 micrograms of estrogen had higher appearances of cavity presence than the control group and the ovariectomy groups (Bixler et al., 1956). This led the researchers to hypothesize increased levels of estrogen may be a factor in the increased rates of cavity appearance (Bixler et al., 1956).

Periodontal Disease

Cavity presence is an important topic in tooth maintenance, however, there is another topic present in the literature: periodontal disease. The periodontium is an important supporting structure to the tooth (Holt, Roberts, & Scully, 2001). It is composed of the gingiva, periodontal ligament, cementum, and alveolar bone which all function to attach to the tooth and provide a protective barrier to the roots and nerves (Holt, Roberts, & Scully, 2001). Oftentimes, harmful bacteria cause gingivitis as it builds upon the surfaces of the periodontium and hardens (Figure 7a & 7b)(Mascarenhas et al., 2002). Once this condition gets worse and the bacteria hardens

enough to cause gingival and alveolar bone loss, the infection is known as periodontal disease (Figure 8)(Coventry et al., 2000; Mascarenhas et al., 2002).



Figure 7a and 7b. Gingival inflammation during gingivitis. Figure 7b also shows an ulcer caused by severe inflammation. Figure 7a and 7b are from Güncü, Tözüm, & Çağlayan (2005).



Figure 8. Severe periodontal disease, characterized by gingival and alveolar bone loss. This figure is from Coventry et al. (2000).

Many hypotheses for how gonadal steroid hormones may influence periodontal disease prevalence, progression, and severity, including gonadal hormones (Mascarenhas et al., 2002). Testosterone receptors and estrogen receptors α and β are found in the periodontal tissue and the number tends to increase in inflamed or overgrown gingiva (Heldring et al., 2007; Kasasa & Soory, 1996). Although upregulation of steroid hormone receptors appears initially, biologically, the periodontium changes during different points of a person's lifetime in stages such as puberty, menstrual cycle, pregnancy, and menopause (Kasasa & Soory, 1996). Although females tend to be more prone to typical fluctuations of hormones during these times, gonadal steroid hormone fluctuations also occurs during a male's lifetime, but mostly during puberty and old age when they undergo age-dependent decreases of testosterone and estrogen (Mascarenhas et al., 2002).

Changes in hormonal concentrations have been correlated to a change in the subgingival microflora due to increases in harmful bacteria (Kornman & Loesche, 1982; Mascarenhas et al., 2002). Some species of harmful bacteria possess the ability to substitute estrogen for essential

growth factors. There is not a proposed mechanism for how the bacteria can do this, but researchers have found structural similarities in the electron transfer between estrogen and Vitamin K. From this, the researchers hypothesized that steroid hormones might be a substitute for Vitamin K in some pigmented Bacteroides species (Gibbons & Macdonald, 1960). The researchers further hypothesized that this resulted in elevated counts of the harmful bacteria in the periodontium (Gibbons & Macdonald, 1960). Additionally, increased levels of harmful bacteria during puberty in both males and females have been linked to gingival inflammation and bleeding of the gums (Mascarenhas et al., 2002).

The menstrual cycle is controlled by the secretion of gonadal steroid hormones in females until menopause (Mascarenhas et al., 2002). This can be broken down into two phases: a follicular phase and a luteal phase (Mascarenhas et al., 2002). During both the follicular and luteal phases, estrogen levels increase. At the end of these phases, if fertilization has not occurred, estrogen levels decline (Mascarenhas et al., 2002). Generally, two different effects on the periodontium occur during menstruation: gingival bleeding and increased inflammatory response (Kribbs & Chestnut, 1984). Additionally, there is a correlation with higher ulcer and lesion rates during the luteal phase of menstruation, however, there is no causal link because the mechanism for gonadal steroid hormone influence is unclear (Mariotti, 1994; Mascarenhas et al., 2002; Segal et al., 1974).

During pregnancy in females, estrogen levels are continuously elevated (Apoorva & Sucheta, 2010; Mascarenhas et al., 2002). Pregnant women are at higher risk for periodontal disease because of these fluctuations in combination with changes in oral flora and decreased immune response (Apoorva & Sucheta, 2010; Mascarenhas et al., 2002; Silk et al., 2008). An increase in estrogen levels can be harnessed by harmful periodontal bacteria which use the

estrogen as a growth factor substitute (Kornman & Loesche, 1982). This can cause an increase in bacterial growth and lead to periodontal disease (Mascarenhas et al., 2002). Furthermore, increased levels of gingival bleeding, inflammation, and ulceration occur during pregnancy (Apoorva & Sucheta, 2010; Mascarenhas et al., 2002). Overall, the increase in bacteria is generally increased in the gingiva which correlates to gingivitis and can lead to increased periodontal disease (Apoorva & Sucheta, 2010).

Additionally, an *Epulis Gravidarum* (pregnancy tumor) can develop as a result of gingival enlargement during pregnancy (Figure 9a & 9b) (Steinberg et al., 2013). This benign lesion occurs most frequently in areas of gingival inflammation or advanced periodontal disease as a result of poor gingival health hypothesized because bacteria can substitute estrogen as necessary nutrients needed for growth (Steinberg et al., 2013). Although this tumor is often not harmful to the patient, the American Dental Association (ADA) stresses the importance of proper dental care during pregnancy to prevent the harmful effects of gingivitis that may lead to advanced periodontal disease (Steinberg et al., 2013).

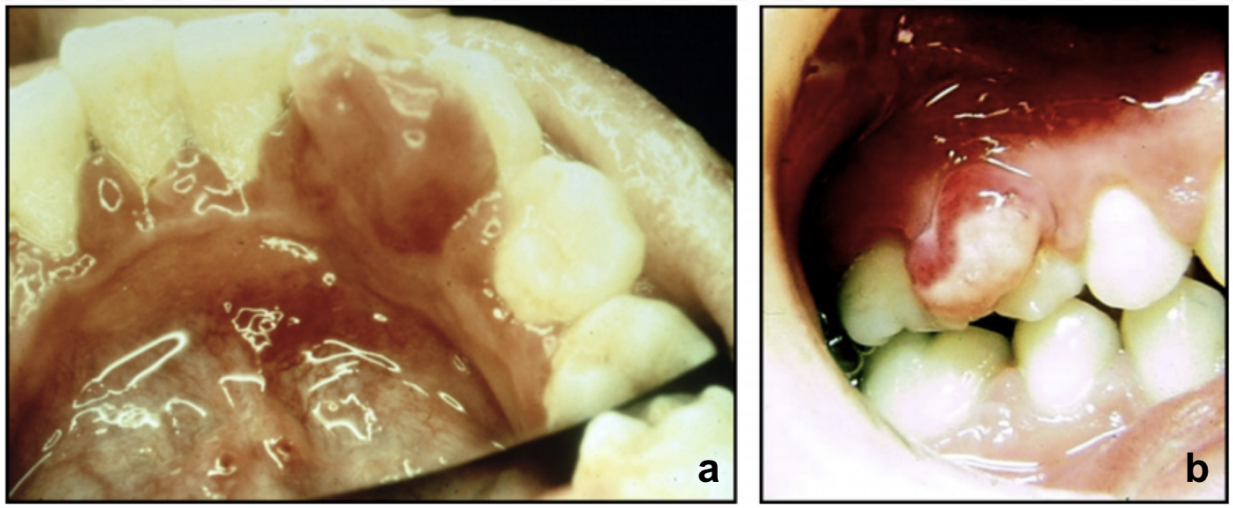

Figure 9a and 9b. *Epulis Gravidarum* (pregnancy tumor) formed in the gingiva of teeth. Figures are from Steinberg et al. (2013).

As females approach menopause, estrogen levels begin to drop (Mascarenhas et al., 2002). This may decrease the inflammatory response that estrogen has on the periodontium (Apoorva & Sucheta, 2010) Also, menopause is categorized by a change in circulating estrogen and testosterone levels in females. During menopause, enzymes convert testosterone to estrogen more frequently than during the menstruation cycle (Mascarenhas et al., 2002). Testosterone has an inhibitory effect on osteoclast function through transcriptional regulation (Güncü, Tözüm, & Çağlayan, 2005). Since testosterone is actively being converted to estrogen, there is evidence that alveolar bone mineral density in the tooth is lower without the osteoclast inhibition from testosterone (Davidson et al., 1982; Steinberg et al., 1989). Additionally, the severity of a decreased alveolar bone mineral density from osteoclast influence has been linked to tooth loss (Elders et al., 1992). Overall, menopause has been hypothesized to promote increased reports of periodontal disease (Elders et al., 1992; Mascarenhas et al., 2002).

In the general population, older males have been reported to have higher levels of periodontal disease than females (Haytac, Ozeclik, & Mariotti, 2013). This occurs specifically when testosterone levels decrease and remain very low (Haytac, Ozeclik, & Mariotti, 2013; Kellesarian et al., 2017). Currently, there is no known cause to why this occurs in older populations, however, there is no conclusive link between testosterone levels and periodontal disease (Haytac, Oeclik, & Mariotti, 2013; Kellesarian et al., 2017). The only hypothesize that exists is that, without testosterone, osteoclasts lack the inhibitory factor this gonadal steroid hormone offers on its transcriptional regulation (Davidson et al., 1982; Steinberg et al., 1989) Although this hypothesis exists, there is only correlational evidence that gonadal steroid difference is a risk for the onset of periodontal disease in males (Haytac, Oeclik, & Mariotti, 2012; Kellesarian et al., 2017).

Discussion

Gonadal steroid hormones serve as a factor in tooth development, growth, and maintenance. Teeth must develop properly and stay healthy throughout a person's lifetime to preserve one's overall health since dental infections have been linked to poor health conditions (Bergqvist, 2003). Many health conditions have been related to abnormalities in aspects of development, growth, and maintenance that are influenced by gonadal steroid hormones (Dumitrescu, 2016; Garcia, Henshaw, & Krall, 2001; Miles, 1954; Ylöstalo et al., 2006).

Development & Growth

During dental development and growth, there can be abnormalities that arise in teeth. In humans, individuals with a certain amount of variation or anatomical deviations that are different from normal are classified to have malformations (Miles, 1954). In the literature, not much is known about malformations during development (Miles, 1954). The two studies that have looked into these malformations have found they occur during a disruption in hard tissue formation and the tooth-eruption process (Lunder, 2015; Miles, 1954).

Some common dental malformations appear frequently mentioned in the literature, however, their cause is still unknown (Miles, 1954). It is very common for teeth to be absent or reduced in size (Miles, 1954). Additionally, other malformations include enamel invagination that can form on surfaces of the tooth's crown or protruding dentin that is not covered by enamel (Miles, 1954).

Although there is no known literature explaining how these dental malformations occur, given what is known about the role of gonadal steroid hormones and the hard tissue formation and tooth eruption processes, I believe that there could be a link between gonadal steroid

hormones and these processes that may lead to malformations. During this process, I hypothesize that a disruption in hormones may lead to a disruption in their role as a transcriptional regulator in hard tissue formation. This could lead to decreases in osteoblast and odontoblast differentiation, which may lead to absent teeth or invaginations on the crown's surfaces. Osteoblasts and odontoblasts respond to testosterone and estrogen when they bind to receptors on the cell membrane or they diffuse through the cell and bind to receptors in the cytoplasm (Miller, 1988). After this process occurs, the steroid-hormone receptor complex moves to the nucleus and binds to DNA sequences called hormone response elements (HREs) to stimulate or inhibit the production of specific messenger RNA (mRNA) through transcription (Miller, 1988). If stimulated, the mRNA can continue along with the cellular process into translation and protein synthesis which leads to cellular differentiation (Miller, 1988). During hard tissue formation, gonadal hormones may increase the number of osteoblasts and odontoblasts present, acting subsequently to build up dentin, enamel, and cementum (Dale et al., 2002).

Although there have not been studies looking at the disruption of gonadal steroid concentrations in developing teeth, there is a study that presents evidence that removing other transcription factors will lead to abnormalities in bone development (Komori et al., 1997). In this study, the researchers compared mice with a genomic transcription factor to homozygous mutant mice without a transcriptional factor, The transcription factor, Cbfa1 (core-binding factor), also called Pebp2αA (polyoma enhancer-binding protein), has similar functions in bone development compared to how both testosterone and estrogen function on osteoblasts and odontoblasts (Komori et al., 1997). The removal of this transcription factor resulted in mice with abnormalities in their skeleton or a complete lack of ossification in bones (Komori et al., 1997). Due to this study and the role that gonadal hormones play in tooth hard tissue formation, I hypothesize that

abnormally low concentrations of either testosterone or estrogen during hard tissue formation may be a reason that dental malformations occur. However, since testosterone is converted to estrogen, we cannot conclusively determine if testosterone may cause these changes since the effects could be attributed to estrogen as well.

To identify if there is a link between these malformations and gonadal steroid hormones, future research should focus on elucidating the mechanism by which dental malformations occur to paint a clear picture of what goes wrong that causes their occurrence. This could mean investigating irregular fluctuations in both testosterone and estrogen and their relationship to malformations. One specific future research topic could look into the transcriptional control of osteoblasts and odontoblasts as a result of abnormal fluctuations of both estrogen and testosterone during tooth development. Future researchers could also follow suit of Komori et al. (1997) and limit gonadal steroid hormone concentrations in developing rodent models and see if malformations or other abnormalities occur in teeth as a result. One possible method for how this manipulation could occur is by creating low concentrations and high concentrations of gonadal steroid hormones to rodents while their teeth are developing and comparing malformations occurring in relation to a control group. Additionally, if malformations develop, rodents can be observed over time to see how these malformations may affect a person's systemic health.

Maintenance

With regards to the maintenance of teeth, periodontal disease and cavity formation are two important topics from a public health perspective. Periodontal disease and cavity prevalence can be risk factors for systemic illnesses (Garcia, Henshaw, & Krall, 2001). Both diseases have been linked to cardiovascular disease, atherosclerosis, inflammation, infection, pulmonary

disease, neurological infections, and adverse pregnancy outcomes (Garcia, Henshaw, & Krall, 2001). This is because both dental diseases may lead to infections which can easily travel to other areas of the body through bone cavities, blood, or lymph vessels, and along nerves, causing harm to the cardiovascular and neurological systems (Olsen & Van Winkelhoff, 2000).

My paper shows that both of these dental diseases have been linked to gonadal steroid hormones in some way. An increased number of cavities has been linked to periods of increased estrogen circulating in a female's body (Lukacs & Largaespada, 2006). This normal increase in estrogen is hypothesized to harm processes that preserve teeth from disruptions in the normal oral microflora (Lukacs & Largaespada, 2006). Additionally, evidence from rodent experimentation showed higher concentrations of testosterone may relate to cases of cavity appearance (Bixler et al., 1956; Muhler et al., 1952; Shaw, 1950). Additionally, increased levels of periodontal disease have been noted during times of significant steroid hormone changes in puberty, pregnancy, menopause, post-menopause, and aging populations (Kasasa & Soory, 1996). There are many hypothesized conditions in regards to the prevalence, progression, and severity of periodontal disease (Mascarenhas et al., 2002). However, the main hypothesis is testosterone receptors and estrogen receptors α and β are found in the periodontal tissue and the number of these receptors ends to increase in inflamed or overgrown gingiva which may lead to periodontal disease (Heldring et al., 2007; Kasasa & Soory, 1996).

Although most of the systemic disorders mentioned do not appear until later in life, dental diseases occur throughout a person's lifetime. Dental diseases are especially prevalent during times where normal hormonal fluctuations are frequent: puberty, pregnancy, menopause, post-menopause, and in aging populations. It is important for people to maintain proper oral

hygiene habits and routinely go to the dentist, especially during times when hormonal concentrations are changing and may affect the maintenance of teeth.

Most dentists recommend visiting every six months to help prevent dental problems (Lang et al., 1994). There is strong evidence that an annual dental examination will be beneficial to the patient's health (Lang et al., 1994). Also, Lang et al. (1994) suggest that it is important for patients to go to the dentist regularly during puberty, pregnancy, and late adulthood. These times are important since estrogen and testosterone are rapidly fluctuating and can lead to higher risks of periodontal disease and cavities (Lang et al., 1994). Proper oral hygiene habits, such as tooth brushing and flossing, as well as routine dental care could be a preventative measure for cardiovascular and neurological disorders later in life. However, more research needs to be conducted to link hormones to dental health and systemic health since both dentist and patient education on this topic is limited. This type of research could begin by exploring estrogen and testosterone manipulation in rodent models similar to the experiments conducted by Bixler et al. (1956), Muhler et al. (1952), and Shaw (1950). In this type of study, researchers could note potential casualties between any dental disorders that may occur and future systemic disorders in the rodents. If such correlations exist, future researchers would need to conclude a causal relationship between gonadal steroid hormones and systemic health. In the literature, there are causal links between dental infections and systemic health, however, the bridge between these important aspects of tooth maintenance and dental infections is limited (Olsen & Van Winkelhoff, 2000). I would suggest looking into an experimental design that causally links infections from periodontal health and cavities to systemic health. Furthermore, future experimentation will need to look into separating the effects of both estrogen and testosterone on dental diseases in males and females based on the age of a patient and the gonadal hormone

fluctuation levels at that time of treatment. This will help future practitioners understand how to make proper recommendations to male and female patients based on their sex since the threshold between what these hormones do in males versus females is unclear.

Overall, the goal of future research and its evidence on this topic would allow dentists and other healthcare providers to make the proper recommendations for patients due to the importance hormones hold on the maintenance of teeth.

Important Implications

This field of research is expanding due to the rise in hormone therapy. In the last few decades, there has been an increased need and want for gonadal steroid hormone therapy and replacement (Mascarenhas et al., 2003). Hormonal therapies are currently being used in hormonal replacement in postmenopausal women and aging male populations, hormone replacement in cancer patients, and transgender hormone therapy, among many other medical uses (Mascarenhas et al., 2003). The effects of these treatments on oral health and dental health are a center of focus for new research because of the increased use of these treatments (Mascarenhas et al., 2003). Due to the role gonadal steroid hormones have on the development, growth, and maintenance of teeth, it is important to understand how these treatments may affect the dental and the medical fields in the next few decades because of the link between dental health and systemic health. This topic is especially important in patients with an altered immune system, specifically cancer patients in remission or patients using hormonal therapies for symptom management (Friss et al., 2015). Patients with a lower immune response may not have proper functioning defenses to fight against adverse effects to cavities and periodontal disease in which rates may be increased by hormonal therapy usage.

There are hormonal therapies and replacements for both estrogen and testosterone (Mascarenhas et al., 2003). These treatments can either replace low concentrations of hormones or increase the concentration of gonadal hormones already present in normal concentrations (Mascarenhas et al., 2003). I hypothesize that taking estrogen and testosterone to replace naturally low concentrations of both hormones may have a positive effect on periodontal health. This is because there is evidence that females with low estrogen levels after menopause and males with low testosterone concentrations in aging populations experience poor periodontal health (Haytac, Ozeclik, & Mariotti, 2013; Mascarenhas et al., 2003). Restoring gonadal steroid hormone concentrations to concentrations where there is no significant harm on the oral environment may be beneficial to patients who experience a periodontal decline. However, it is unknown what the threshold for concentrations of steroid hormones to have neutral effects on teeth. Future research will need to explore this idea to fully understand how to restore low concentrations of hormones to a level that causes no harm to periodontal status. Additionally, I hypothesize that patients who take estrogen and testosterone therapies to increase the amount of circulating hormone present in their system (e.g. females on hormonal birth control) may experience harmful effects on periodontal status. Although there is no known cause for how testosterone affects periodontal status, it has been shown to have an inhibitory effect on osteoclast function (Anstead et al., 1997; Santen et al., 2019). In higher concentrations of circulating testosterone, there is evidence that alveolar bone mineral density in the tooth is lower without the osteoclast inhibition from testosterone (Davidson et al., 1982; Steinberg et al., 1989). Similarly, increases in circulating levels of estrogen during puberty and pregnancy have been shown to cause higher rates of periodontal disease (Kornman & Loesche, 1982; Mascarenhas et al., 2002) Some species of harmful bacteria possess the ability to substitute estrogen for essential growth

factors. There is not a proposed mechanism for how the bacteria can do this, but researchers have found structural similarities in the electron transfer between estrogen and Vitamin K. From this, the researchers hypothesized that estrogen might be a substitute for Vitamin K in some Bacteroides species (Gibbons & Macdonald, 1960). The researchers further hypothesized that this resulted in the increased concentration and elevated counts of the harmful bacteria in the periodontium (Gibbons & Macdonald, 1960). Due to these theories present in the field, I hypothesize that increasing circulating levels of both estrogen and testosterone may cause harmful dental side effects in both male and female patients.

Furthermore, I hypothesize that there would be different side effects of cavity presence compared to those experienced for periodontal disease. I hypothesize that taking estrogen and testosterone to replace naturally low concentrations of these hormones may have a negative rate of cavity appearance. Although there is evidence that increasing concentrations of testosterone and estrogen affect the rate of cavity appearance, there has been no information to suggest that low concentrations of both hormones affect any processes in teeth that result in higher rates of cavity appearance (Bixler et al., 1956). Studies have found that rodents who had lower concentrations of gonadal steroid hormones from both ovariectomy and orchiectomy experiments had fewer cavities than control groups with normal fluctuations of hormones (Bixler et al., 1956; Muhler et al., 1952; Shaw, 1950). This could mean that increasing concentrations if a person is deficient in estrogen or testosterone, may cause an increase in tooth demineralization and result in higher rates of cavity appearance. Patients who use hormonal therapies to increase either estrogen and testosterone during times of normal fluctuation may experience an increase in tooth demineralization and cavity appearance. I hypothesize that this could be the case for patients taking estrogen because increased levels of this hormone are hypothesized to affect saliva

production (Lukacs & Largaespada, 2006). The major functions of saliva for teeth are to deny harmful bacteria an optimal pH, neutralize acids, and prevent demineralization of teeth (Lukacs, 2011; Lukacs & Largaespada, 2006). During the demineralization process of teeth, salivary peptides help raise the pH of the tooth surface following the exposure of fermentable carbohydrates (Lukacs, 2011; Lukacs & Largaespada, 2006; Tao et al., 2005). When the salivary rate and composition are diminished during these times of higher concentrations of estrogen, high rates of tooth demineralization are reported in females (Lukacs, 2011). Additionally, experimental studies that increased the concentrations of testosterone in developmental mice found that administration of testosterone to control males appeared to increase cavity appearance in teeth (Bixler et al., 1956; Muhler et al., 1952; Shaw, 1950). This suggested that increased concentrations from the normal amount of testosterone promoted cavity formation (Bixler et al., 1956; Muhler et al., 1952; Shaw, 1950). Due to these studies, I hypothesize that increasing already normal fluctuations of both estrogen and testosterone in both males and females may lead to increased rates of cavity appearance in teeth.

In the literature, there have been hypothesized correlations between these therapies and dental disorders, however, there is no conclusive evidence or research to identify any actual causal relationships between hormone therapies, dental disorders, and systemic health (Mascarenhas et al., 2003). Future research will also need to identify the harmful side effects these treatments have in both non-immunocompromised and immunocompromised patients. Additionally, future research will need to explore what is considered a normal concentration of each gonadal steroid hormone during each stage of a male's and female's lifetime in both non-immunocompromised and immunocompromised patients. This information could lead to researchers understanding what is considered a low concentration or a high concentration in

males and females at the time of treatment. Furthermore, this expanded research could explain what additional concentrations of hormones in the body could do to a person's dental and systemic health. I would suggest, like other studies in this field, looking into the effects of these treatments on rodent models or conducting a longitudinal study on the long-term dental and systemic side effects experienced by patients taking these therapies. This information could lead to proper recommendations and treatments for these types of therapies and replacements for all patients. Overall, future research needs to focus on these unanswered questions to educate doctors, dentists, and other practitioners on the effects these therapies may have on their patients.

Works Cited

Anstead GM, Carlson KE, Katzenellenbogen JA. 1997. The estradiol pharmacophore: Ligand structure-estrogen receptor binding affinity relationships and a model for the receptor binding site. Steroids 62(3):268-303.

Apoorva SM and Suchetha A. 2010. Effect of sex hormones on the periodontium. Indian Journal of Dental Sciences 2(5):36-40

Azenha MR, Homsi G, Garcia IR. 2012. Multiple brain abscess from dental origin: Case report and literature review. Oral and Maxillofacial Surgery 16(4):393-7

Bergqvist LP. 2003. The role of teeth in mammal history. Brazilian Journal of Oral Sciences 2(6):249-57.

Billings F. 1914. Focal infection: Its broader application in the etiology of general disease. Journal of the American Medical Association 63(11):899-903.

Bixler D, Muhler JC, Shafer WG. 1957. The effect of sex hormones on dental caries in desalivated rats. Journal of Dental Research 36(5):709-12.

Boabaid F, Berry JE, Koh AJ, Somerman MJ, McCauley LK. 2004. The role of parathyroid hormone-related protein in the regulation of osteoclastogenesis by cementoblasts. Journal of Periodontology 75(9):1247-54.

Bonten MJ, Gaillard CA, van Tiel FH, Smeets HG, van der Geest S, Stobberingh EE. 1994. The stomach is not a source for colonization of the upper respiratory tract and pneumonia in ICU patients. Chest 105(3):878-84.

Clark D and Levin L. 2019. In the dental implant era, why do we still bother saving teeth? Dental Traumatology 35(6):368-75.

Cohen DW, Friedman L, Shapiro J. & Kyle GC. 1969. A longitudinal investigation of the periodontal changes during pregnancy. Journal of Periodontology 40(10): 563–70.

Corson MA, Postlethwaite KP, Seymour RA. 2001. Are dental infections a cause of brain abscess? Case report and review of the literature. Oral Diseases 7(1):61-5.

Coventry J, Griffiths G, Scully C, Tonetti M. 2000. Periodontal disease. BMJ 321(7252):36-9.

Dale J, Sarich S, Bretz T, Hatton J, Zachow R. 2002. Hormonal regulation of androgen receptor messenger ribonucleic acid expression in human tooth pulp. Journal of Dental Research 81(5):360–5.

Davidson, BJ, Ross, RK, Paganini-Hill A, Hammond GD, Siiteri PK. & Judd HL. 1982. Total and free estrogens and androgens in postmenopausal women with hip fractures. Journal of Clinical Endocrinology and Metabolism 54(1):115–120.

Decaroli MC and Rochira V. 2017. Aging and sex hormones in males. Virulence 8(5):545-70.

Dempsey PJ, Townsend GC, Richards LC. 1999. Increased tooth crown size in females with twin brothers: Evidence for hormonal diffusion between human twins in utero. American Journal of Human Biology: The Official Journal of the Human Biology Association 11(5):577-86.

DeStefano F, Anda RF, Kahn HS, Williamson DF, Russell CM. 1993. Dental disease and risk of coronary heart disease and mortality. British Medical Journal 306(6879):688-91.

Dimitrakakis C and Bondy C. 2009. Androgens and the breast. Breast Cancer Research 11(5):1-9

Dumitrescu AL. 2016. Periodontal disease–A public health problem. Frontiers in Public Health 3(1):278.

Elders P, Habets L, Netelenbos JC, van der Linden, L W J, van der Sieit, P F. 1992. The relation between periodontitis and systemic bone mass in women between 46 and 55 years of age. Journal of Clinical Periodontology 19(7):492-6.

Eriksen EF, Colvard DS, Berg NJ, Graham ML, Mann KG, Spelsberg TC, Riggs BL. 1988. Evidence of estrogen receptors in normal human osteoblast-like cells. Science 241(4861):84-6.

Freeman ER, Bloom DA, McGuire EJ. 2001. A brief history of testosterone. Journal of Urology 165(2):371-3.

Friis S, Kesminiene A, Espina C, Auvinen A, Straif K, Schüz J. 2015. European code against cancer 4th edition: Medical exposures, including hormone therapy, and cancer. Cancer Epidemiology 39(1):107-19.

Fujiwara N and Fujimura A. 2019. Insulin-like growth factor-I stimulates the disintegration of Hertwig's epithelial root sheath and cellular cementogenesis in mouse molars in vitro. Dental Journal of Iwate Medical University 43(3):140-52.

Garcia RI, Henshaw MM, Krall EA. 2001. Relationship between periodontal disease and systemic health. Periodontology 2000 25(1):21-36.

Garn SM, Lewis AB, Koski K, Polacheck DL. 1958. The Sex Difference in Tooth Calcification. Journal of Dental Research 37(3):561–67.

Güncü GN, Tözüm TF, Çağlayan F. 2005. Effects of endogenous sex hormones on the periodontium—review of literature. Australian Dental Journal 50(3):138-45.

Gibbons RJ and Macdonald JB. 1960. Hemin and vitamin K compounds as required factors for the cultivation of certain strains of *Bacteroides melaninogenicus*. Journal of Bacteriology 80(2):164.

Haytac MC, Ozcelik O, Mariotti A. 2013. Periodontal disease in men. Periodontology 2000 61(1):252-65.

Heldring N, Pike A, Andersson S, Matthews J, Cheng G, Hartman J, Tujague M, Strom A, Treuter E, Warner M. 2007. Estrogen receptors: How do they signal and what are their targets. Physiological Reviews 87(3):905-31.

Hietala E, Larmas M, Salo T. 1998. Localization of estrogen-receptor-related antigen in human odontoblasts. Journal of Dental Research 77(6):1384-7.

Holt R, Roberts G, Scully C. 2001. Oral health and disease. Western Journal of Medicine 174(3):199.

Hovorakova M, Lesot H, Peterka M, Peterkova R. 2018. Early development of the human dentition revisited. Journal of Anatomy 233(2):135-45.

Jernvall J and Thesleff I. 2012. Tooth shape formation and tooth renewal: Evolving with the same signals. Development 139(19):3487-97.

Kasasa SC, Soory M. 1996. The effects of interleukin-1 (IL-1) on androgen metabolism in human gingival tissue (HGT) and periodontal ligament (PDL). Journal of Clinical

Periodontology 23(3): 419-24.

Kellesarian SV, Malmstrom H, Abduljabbar T, Vohra F, Kellesarian TV, Javed F, Romanos GE. 2017. “Low testosterone levels in body fluids are associated with chronic periodontitis” A reality or a myth? American Journal of Men's Health 11(2):443-53.

Komori T, Yagi H, Nomura S, Yamaguchi A, Sasaki K, Deguchi K, Shimizu Y, Bronson RT, Gao Y, Inada M. 1997. Targeted disruption of Cbfa1 results in a complete lack of bone formation owing to maturational arrest of osteoblasts. Cell 89(5):755-64.

Kornman KS and Loesche WJ. 1982. Effects of estradiol and progesterone on *Bacteroides melaninogenicus* and *Bacteroides gingivalis*. Infection and Immunology 35(1):256-63.

Kribbs PJ and Chesnut III CH. 1984. Osteoporosis and dental osteopenia in the elderly. Gerodontology 3(2):101-6.

Lang WP, Farghaly MM, Ronis DL. 1994. The relation of preventive dental behaviors to periodontal health status. Journal of Clinical Periodontology 21(3):194-8.

Levine M. 2013. Understanding how a dental infection may spread to the brain: Case report. Journal of Canadian Dental Association. 79(1): d9

Li H, Bartold PM, Zhang CZ, Clarkson RW, Young WG, Waters MJ. 1998. Growth hormone and insulin-like growth factor I induce bone morphogenetic proteins 2 and 4: A mediator role in bone and tooth formation? Endocrinology 139(9):3855-62.

Luder HU. 2015. Malformations of the tooth root in humans. Frontiers in Physiology 6(1):307.

Lukacs JR. 2011. Sex differences in dental caries experience: Clinical evidence, complex etiology. Clinical Oral Investigations 15(5):649-56.

Lukacs JR, Largaespada LL. 2006. Explaining sex differences in dental caries prevalence: Saliva, hormones, and "life-history" etiologies. American Journal of Human Biology 18(4):540–55.

Marks SC, Gorski JP, Wise GE. 1995. The mechanisms and mediators of tooth eruption--models for developmental biologists. International Journal of Developmental Biology 39(1):223-30.

Marks SC and Schroeder HE. 1996. Tooth eruption: Theories and facts. The Anatomical Record: An Official Publication of the American Association of Anatomists 245(2):374-93.

Mariotti, A. 1994. Sex steroid hormones and cell dynamics in the periodontium. Critical Reviews in Oral Biology and Medicine 5(1):27– 53.

Mascarenhas P, Gapski R, Al‐Shammari K, Wang H. 2003. Influence of sex hormones on the periodontium. Journal of Clinical Periodontology 30(8):671-81.

Miles A. 1954. Malformations of the Teeth. Proceedings of the Royal Society of Medicine 817-836.

Miller WL. 1988. Molecular biology of steroid hormone synthesis. Endocrine Reviews 9(3):295-318.

Muhler JC and Shafer WG. 1952. Experimental dental caries: The effect of orchiectomy and ovariectomy on dental caries in immature rats. Journal of Dental Research 31(6):798-804.

Noden DM. 1984. Craniofacial development: New views on old problems. The Anatomical Record 208(1):1-13.

Olsen I and Van Winkelhoff AJ. 2014. Acute focal infections of dental origin. Periodontology 200065(1):178-89.

Pussinen PJ, Alfthan G, Jousilahti P, Paju S, Tuomilehto J. 2007. Systemic exposure to porphyromonas gingivalis predicts incident stroke. Atherosclerosis 193(1):222-8.

Rathee M and Jain P. 2020. Embryology, teeth. StatPearls [Internet].

Renvert S, Pettersson T, Ohlsson O, Persson GR. 2006. Bacterial profile and burden of periodontal infection in subjects with a diagnosis of acute coronary syndrome. Journal of Periodontology 77(7):1110-9.

Ribeiro DC, Brook AH, Hughes TE, Sampson WJ, Townsend GC. 2013. Intrauterine hormone effects on tooth dimensions. Journal of Dental Research 92(5):425-31.

Ribeiro DC. 2012. Increased tooth crown size in females from opposite-sex dizygotic twins: A possible intrauterine hormonal influence on dental development. Doctoral dissertation. Adelaide, Australia: The University of Adelaide. 221p.

Rudolph LM, Cornil CA, Mittelman-Smith MA, Rainville JR, Remage-Healey L, Sinchak K, Micevych PE. 2016. Actions of steroids: New neurotransmitters. Journal of Neuroscience 36(45):11449-58.

Santen RJ and Simpson E. 2019. History of estrogen: Its purification, structure, synthesis, biologic actions, and clinical implications. Endocrinology 160(3):605-25.

Sanz M, D'Aiuto F, Deanfield J, Fernández-Avilés F. 2010. European workshop in periodontal health and cardiovascular disease—scientific evidence on the association between periodontal and cardiovascular diseases: A review of the literature. European Heart Journal Supplements 12(supplement B):3-12.

Segal, AL, Katcher, AH, Brightman, VJ & Miller, MF. 1974. Recurrent herpes labialis, recurrent aphthous ulcers, and the menstrual cycle. Journal of Dental Research 53(4): 797–803.

Selwitz RH, Ismail AI, Pitts NB. 2007. Dental caries. The Lancet 369(9555):51-9.

Shaw JH. 1950. Studies on effect of gonadectomy on dental caries activity in white rats and in cotton rats. Journal of Dental Research 29(6):798-801.

Silk H, Douglass AB, Douglass JM, Silk L. 2008. Oral health during pregnancy. American Family Physician 77(8):1139-44.

Steinberg BJ, Hilton IV, Iida H, Samelson R. 2013. Oral health and dental care during pregnancy. Dental Clinics 57(2):195-210.

Steinberg, KK, Freni-Titulaer, LW, DePuey, EG, Miller, DT, Sgoutas, DS, Coralli, CH, Phillips, DL, Rogers, TN & Clark, RV. 1989. Sex steroids and bone density in premenopausal and perimenopausal women. Journal of Clinical Endocrinology and Metabolism 69 (3):533–39.

Stewart NA, Molina GF, Issa JPM, Yates NA, Sosovicka M, Vieira AR, Line SRP, Montgomery J, Gerlach RF. 2016. The identification of peptides by nanoLC-MS/MS from human

surface tooth enamel following a simple acid etch extraction. Royal Society of Chemistry Advances 6(66):61673-9.

Tao R, Jurevic RJ, Coulton KK, Tsutsui MT, Roberts MC, Kimball JR, Wells N, Berndt J, Dale BA. 2005. Salivary antimicrobial peptide expression and dental caries experience in children. Antimicrobial Agents Chemotherapy 49(9):3883-8.

Thesleff I and Nieminen P. 1996. Tooth morphogenesis and cell differentiation. Current Opinion in Cell Biology 8(6):844-50.

Van Wagenen G and Hurme VO. 1950. Effect of testosterone propionate on permanent canine tooth eruption in the monkey (*Macaca mulatta*). Proceedings of the Society for Experimental Biology and Medicine 73(2):296-7.

Weise M, De-Levi S, Barnes KM, Gafni RI, Abad V, Baron J. 2001. Effects of estrogen on growth plate senescence and epiph yseal fusion. Proceedings of the National Academy of Sciences 98(12):6871–6.

Wierman ME. 2007. Sex steroid effects at target tissues: Mechanisms of action. Advanced Physiological Education 31(1):26-33.

Wiren KM, Zhang X, Chang C, Keenan E, Orwoll ES. 1997. Transcriptional up-regulation of the human androgen receptor by androgen in bone cells. Endocrinology 138(6):2291-300.

Ylöstalo PV, Järvelin MR, Laitinen J, Knuuttila ML. 2006. Gingivitis, dental caries and tooth loss: Risk factors for cardiovascular diseases or indicators of elevated health risks. Journal of Clinical Periodontology 33(2):92-101.

Yu T and Klein OD. 2020. Molecular and cellular mechanisms of tooth development, homeostasis and repair. Development 147(2):1-15.